

# ADULT ORTHODONTICS CASE TREATED WITH INVISIBLE BRACES



BEFORE



AFTER

## HAPPY BRACES

## SMILE VIEW


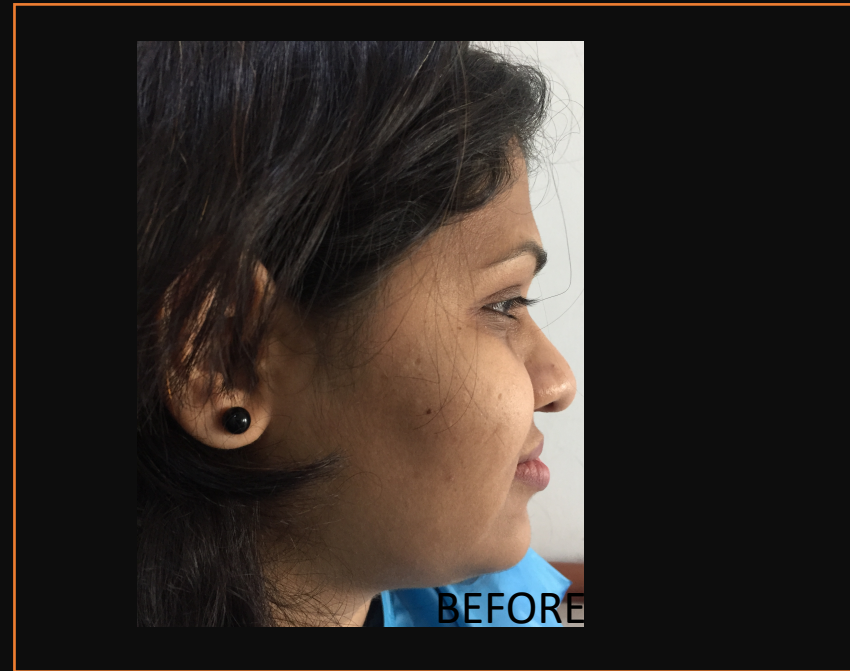
- Patient has a more confident smile post treatment.
- Also, the smile arc has Improved.

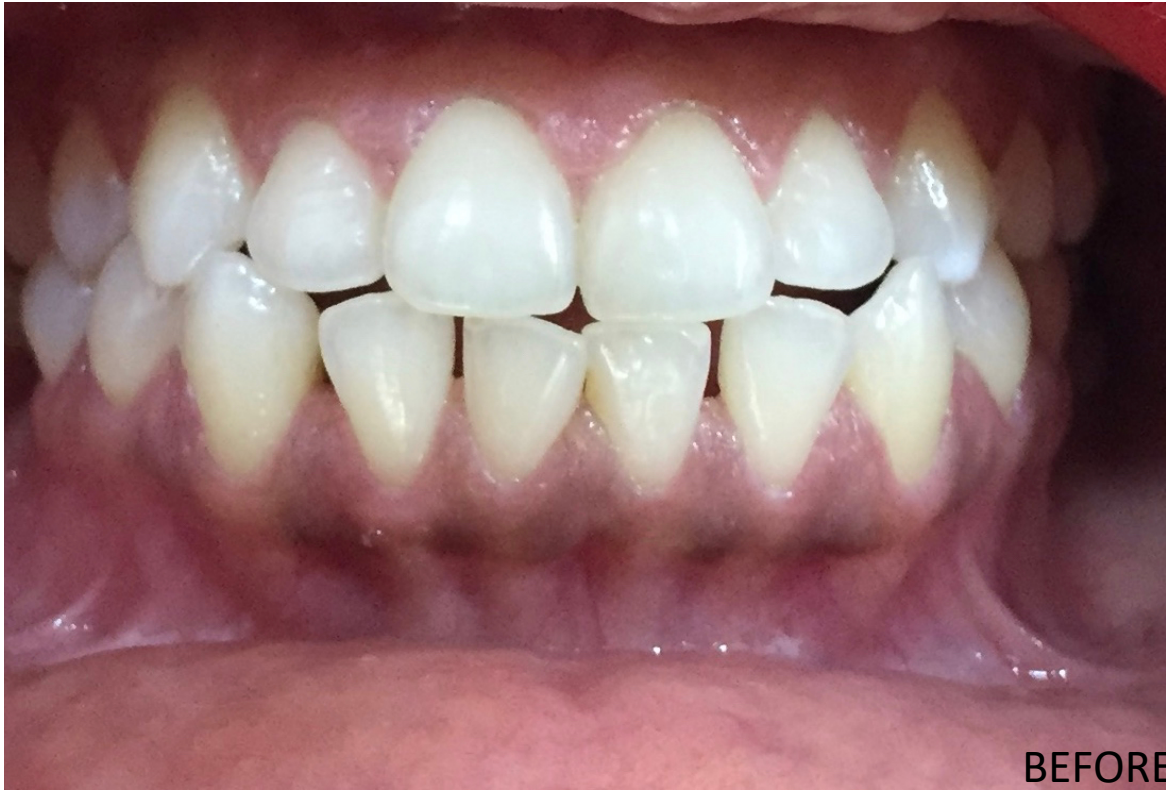

# PROFILE VIEW

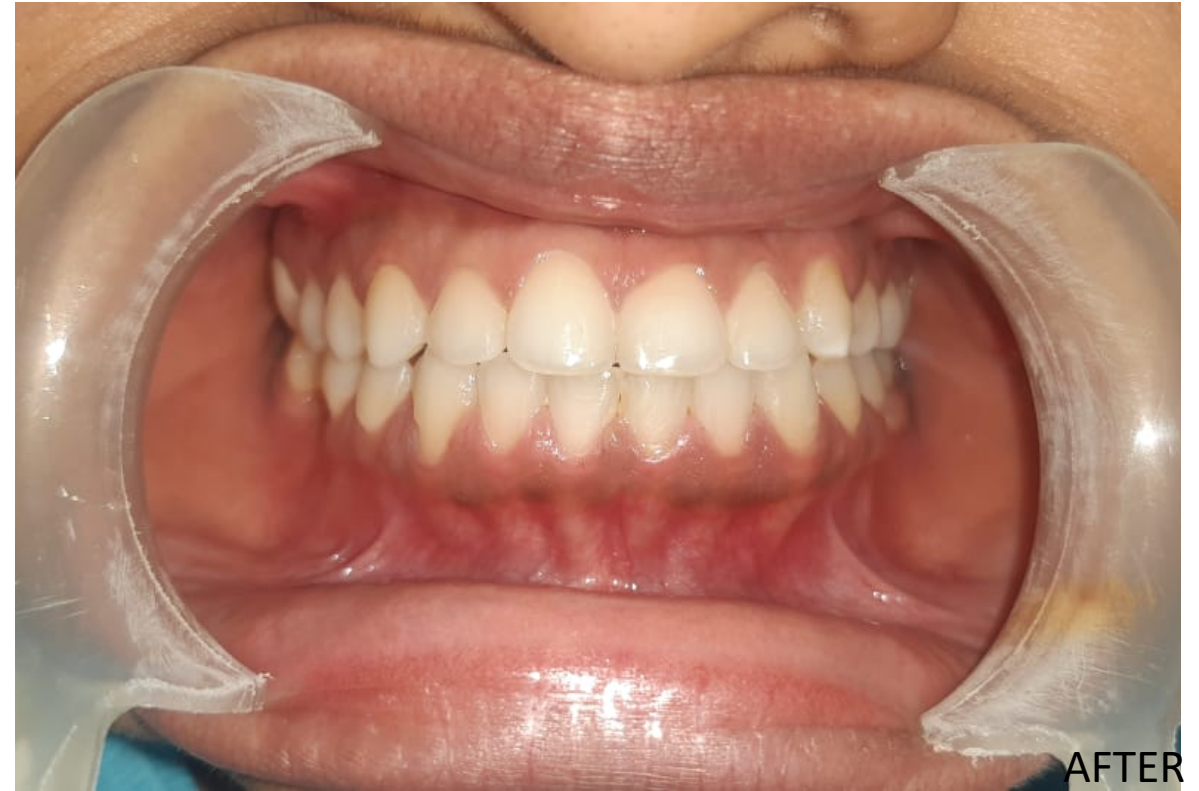---

- Profile has become nearly straight after treatment as compared to concave pre treatment.
- The case was treated without extractions.





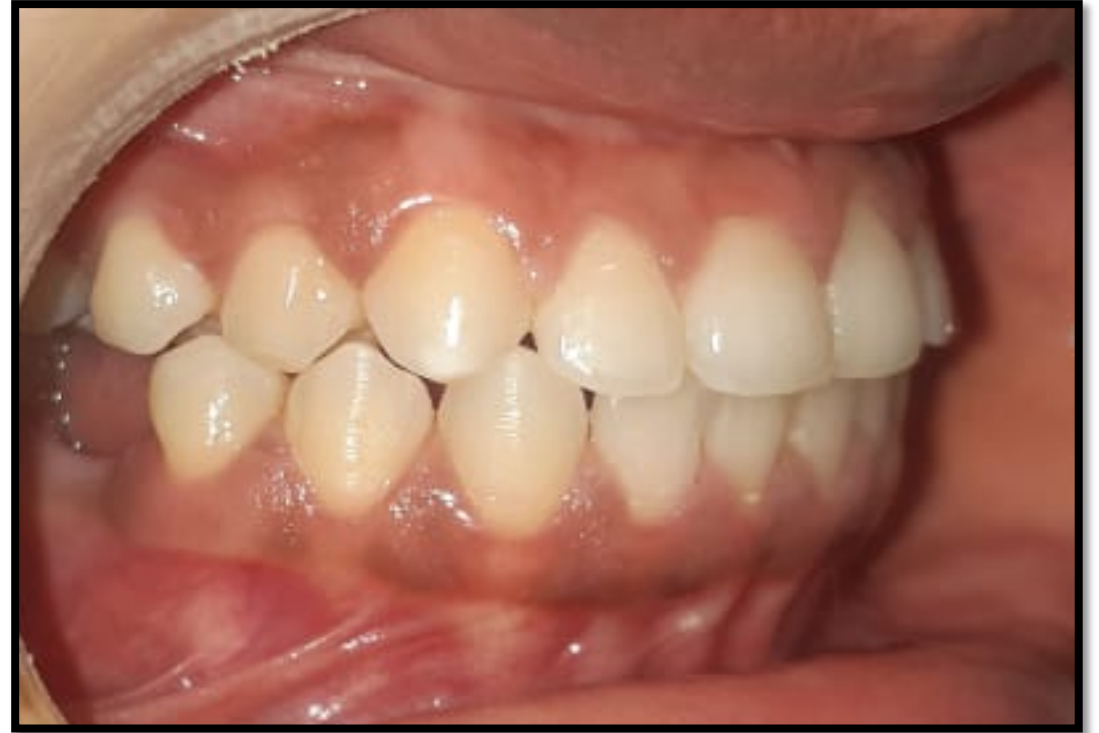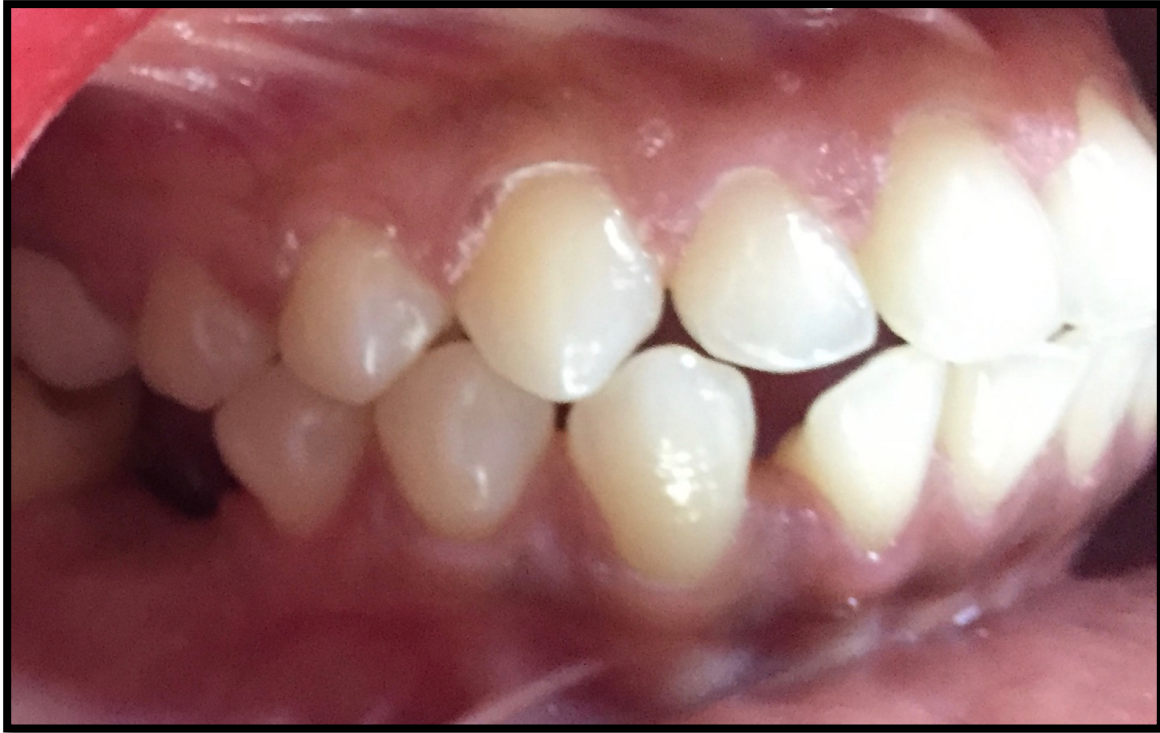BEFORE



AFTER

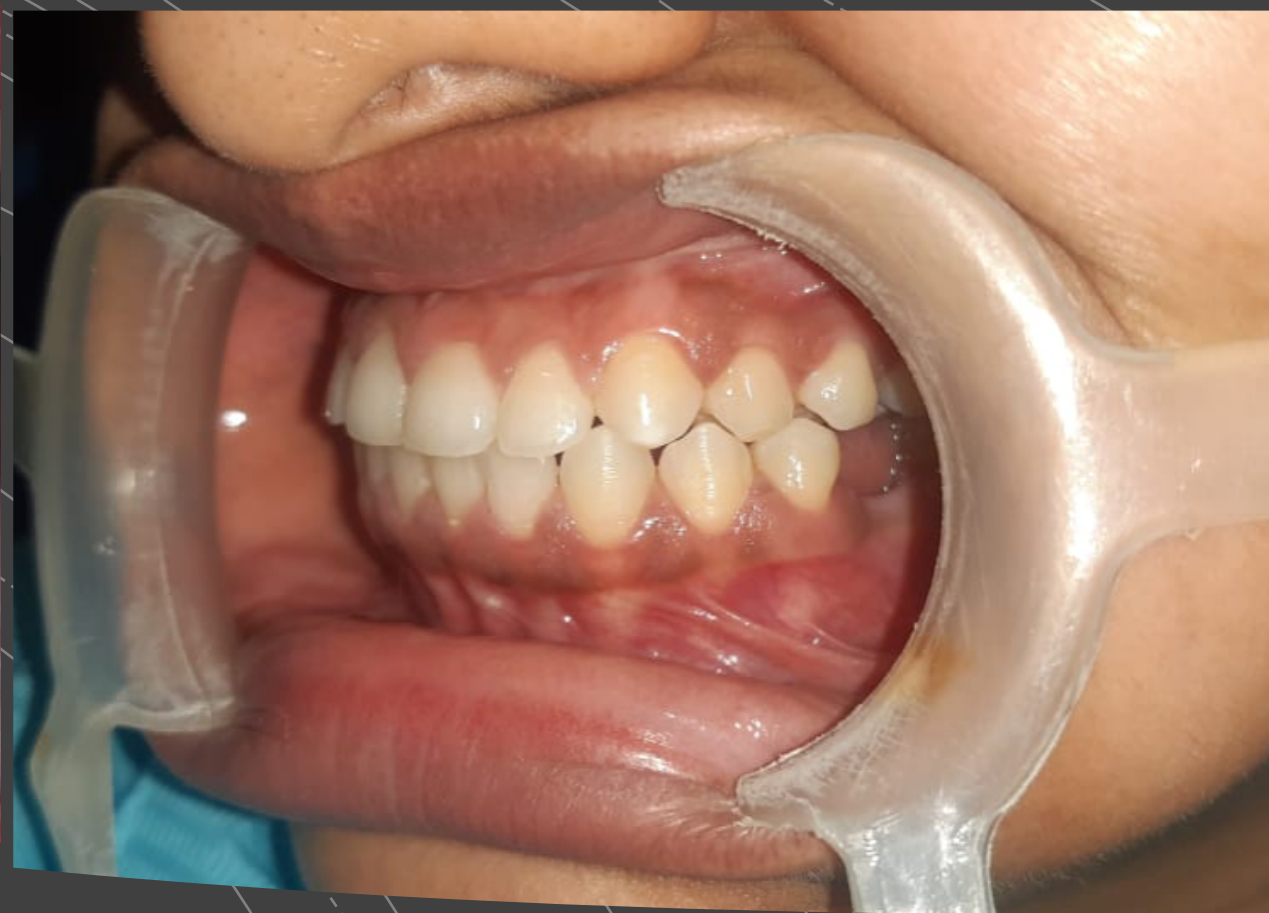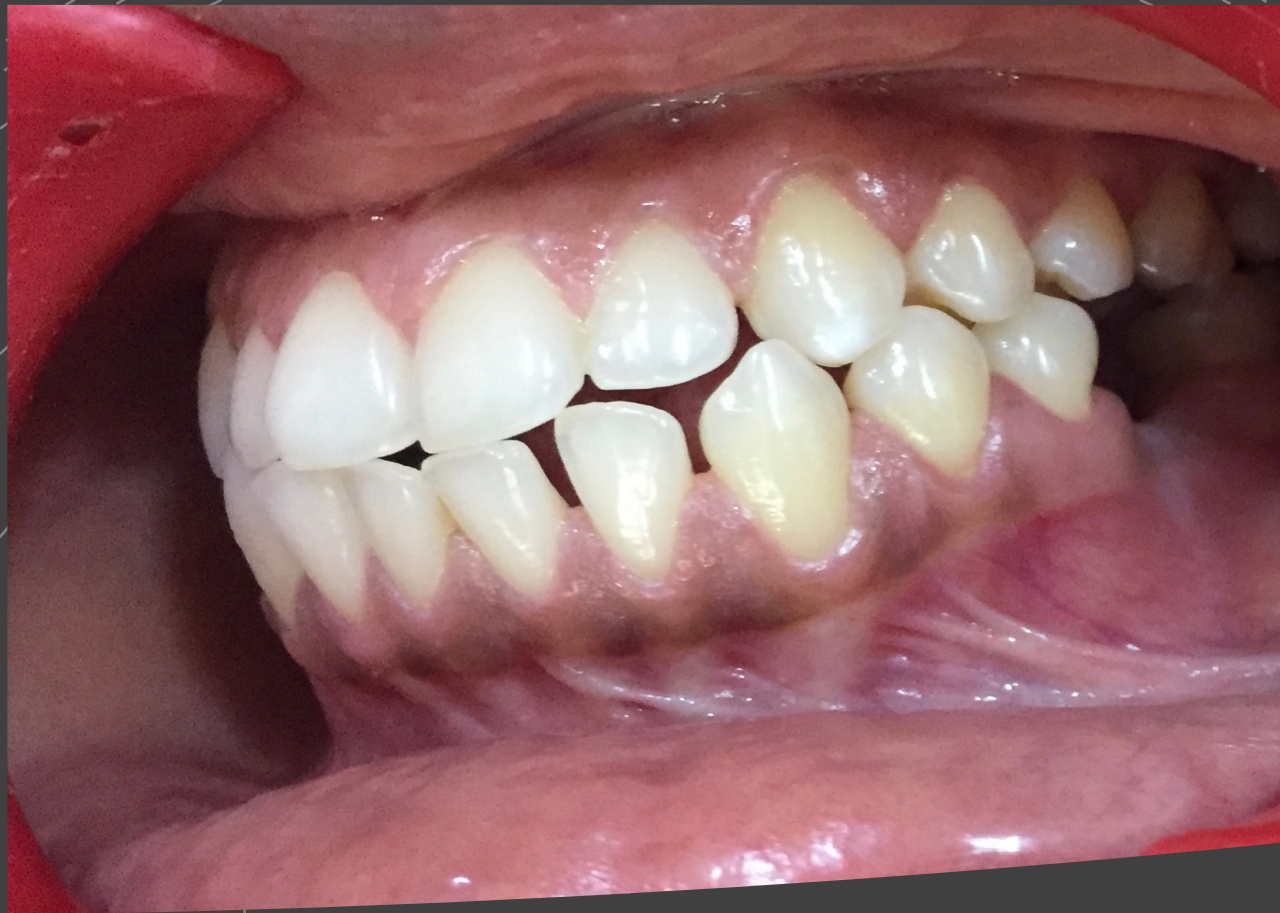INTRAORAL : FRONT

- Edge to edge , traumatic bite before treatment
- Normal overjet, overbite and coinciding midline after treatment.



RIGHT OCCLUSAL VIEW:  
POST TRETMENT CANINE GUIDED OCCLUSION  
PROSTHETIC REPLACEMENT OF 46 PLANNED (IMPLANT)

---



## LEFT OCCLUSAL VIEW

- POST TRETMENT CANINE GUIDED OCCLUSION.
- PROSTHETIC REPLACEMENT OF 36 PLANNED ( IMPLANT)